



PATIENT

Sammy Olmstead

SPECIES

Feline

BREED

DLH

SEX

Male Neutered

AGE

15 years

WEIGHT

8.62lbs

INTERPRETED BY

Maggie Machen
Lamy, DVM, DACVIM
(Cardiology)

IMAGING PERFORMED BY

Jenna Walch, CVT

HOSPITAL NAME

Santa Clara Animal
Hospital

REFERRING VET

Dr. Giddens

INVOICE

27221

DATE

11/1/22

PRESENTING CLINICAL SIGNS

History: Grade 2/6 heart murmur. Assess prior to dental. Sedated with Torb and on IVF for a few hours before ultrasound at low rate.
-Abnormal PE/Chem/CBC/UA Results: Elevated Renal values/SDMA, and elevated WBC, low HCT

ECHOCARDIOGRAM FINDINGS

2D, m-mode, color flow and doppler imaging is available. The left ventricular wall thickness is irregular without significant hypertrophy. There is a diffusely hyperechoic endocardium consistent with fibrosis and ventricular remodeling. The left ventricular chamber is normal in dimension. The papillary muscles appear mildly remodeled and asymmetric. The left atrium is normal in size. The right atrium is prominent. The right ventricle is irregular as well. The mitral valve is normal in structure and mobility. There is no mitral regurgitation present. Moderate tricuspid regurgitation is identified. Normal velocity. Blood flow through both the LVOT and RVOT are normal in velocity. Trace PI and AI. No effusions or cardiac tumors identified.

CARDIAC CHART

FELINE CARDIAC PARAMETERS	BODY WEIGHT (kg)	HR (BPM)	IVSd (cm) (Moise, Pipers)	LVIDd (cm) (Moise, Pipers)	LVWd (cm) (Moise, Pipers)	FS (%)	EF (%)
NORMAL PARAMETER	-----	150-240	0.35-0.55	<2 (mean 1.5)	3.5-0.55	35-67	80-100
PATIENT	3.9	188	0.4	1.6	0.4	55	86
FELINE CARDIAC PARAMETERS	LA/AO (Boon)	LA/AO HEART BASE (Swe) (Abbott)	LA 2D short axis Base view (cm) (Abbott)		LVOT VEL (m/s)	RVOT VEL (m/s)	E max (m/s)
NORMAL	<1.5	<1.3	<1.2		<1.6	<1.3	<0.9
PATIENT	1.3	1.3	1.2		1.2	1.1	NM
<p><i>*Note: All measurements based upon multi-modal images and methods. An average value is reported.</i> Adapted from June Boon, Veterinary Echocardiography, 1998 Abbott J & MacLean H JVIM 2006;20: 111-119, Moise et al. Am J Vet Res 47:1476, 1986. Pipers et al. Am J Vet Res 40:882, 1979.</p>							

INTERPRETATION OF THE FINDINGS & FURTHER RECOMMENDATIONS

The only abnormality identified is moderate tricuspid regurgitation. TR in cats is often physiologic, however in this case the volume is significant and there is a prominent right atrium making it more concerning. There is also a significant amount of remodeling and fibrosis of both ventricular walls which is of unknown relevance at this juncture. A small aortic insufficiency is appreciated, and a baseline blood pressure is recommended. No additional issues are identified.

Given these findings, no medications are indicated.

Anesthetic risk is considered mild. With this degree of remodeling and diastolic stiffening, there is an elevated risk for fluid overload in this patient and judicious IV fluid use is recommended. Heart rate stimulating drugs such as atropine, glycopyrrolate or ketamine should be avoided unless medically necessary.



PATIENT

Sammy Olmstead

Monitor in the future for respiratory compromise, syncope/lethargy, or signs of a blood clot (paralysis, lameness).

SPECIES

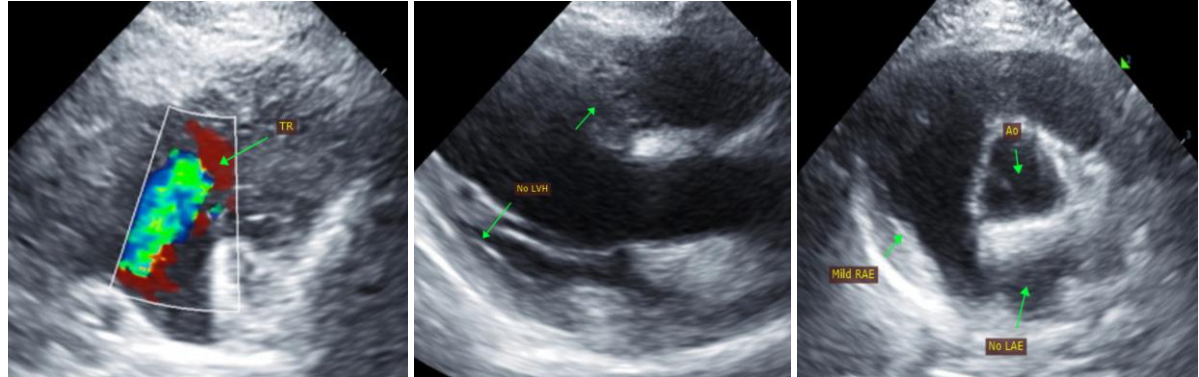
Feline

Recommend recheck echocardiogram in 6-12 months to assess for progression.

BREED

DLH

IMAGES



SEX

Male Neutered

AGE

15 years

WEIGHT

8.62lbs

The information and recommendations provided are based on the images presented by the referring veterinarian. No evaluation can be communicated regarding pathology that was not visible in the image/video clips provided.

INTERPRETED BY

Maggie Machen Lamy, DVM, DACVIM (Cardiology)

Thank you for this referral. This report was generated using transcription software, and minor dictation errors may be present. If the clinical or image interpretation does not parallel your findings or if I can be of any further assistance, please contact me.

Maggie Machen Lamy, DVM
 Diplomate of the American College of Veterinary Internal Medicine (Cardiology)
 info@sonopath.com

IMAGING PERFORMED BY

Jenna Walch, CVT

HOSPITAL NAME

Santa Clara Animal Hospital

REFERRING VET

Dr. Giddens

INVOICE

27221

DATE

11/1/22